Supracondylar Fractures & Evaluation for Arterial Injury

Supplement to Presentation
Evan Kuhl
May 8, 2019

Case Presentation:

32-year-old male with no past medical history presenting by AMR after a scooter accident just prior to arrival. Patient states that he was riding a scooter at unknown speed and fell forward onto his outstretched arms without loss of consciousness. In triage, the patient was found to have an obvious deformity to the right humerus, with an open wound, without a palpable radial pulse. The patient endorsed decreased sensation to all fingers. From triage the patient was activated as a trauma and taken to the trauma bay.

During the trauma activation, the patient was found to have no dopplerable radial pulse. Physical exam revealed a 10cm laceration with exposed humerus and significant swelling to the elbow. The hand was reported to be dusky with subjectively decreased sensation and no palpable radial or ulnar pulses. Ancef, tetanus vaccine, and fentanyl were given in the trauma bay and the patient was taken to CT, which revealed a 5 cm segment occlusion of the distal brachial artery and an open, comminuted and displaced supracondylar fracture.

The patient was taken to the operating room by vascular for wound exploration with a plan for possible bypass with a saphenous vein harvest, however upon exploration the patient was found to have an intact brachial artery with thrombus, and an open thrombectomy of the right brachial artery with patch angioplasty was performed. Orthopedics then applied an external fixator. Postoperatively the patient had palpable radial pulse and cap refill <3 seconds. The patient had a nonfunctioning flexor pollucus longus and flexor digitorum profundus, indicating a potential median nerve injury.

The patient was taken to the ICU for q1h neuro checks and was downgraded on POD 2, with improvement in FPL and FDP function. Required APS consult for pain control with lidocaine and ketamine. 5 days after the index surgery, the patient underwent debridement and ORIF placement.

Supracondylar Fractures

Most common elbow fracture in patients < 8 years old, up to 95% are from FOOSH extension injuries. Physical exam may identify refusal to range the elbow, tenderness along the posterior distal humerus, or “S” or “Pucker” signs. Imaging should include a true lateral elbow film and forearm views. Imaging should be reviewed for appropriate alignment of the radial head, capitellum, and anterior humerus. A posterior fat pad or anterior sail sign should raise suspicion for an occult fracture. Posterior fat pads typically indicate an occult supracondylar fracture in pediatrics, while adults are more likely to have a radial head fracture.

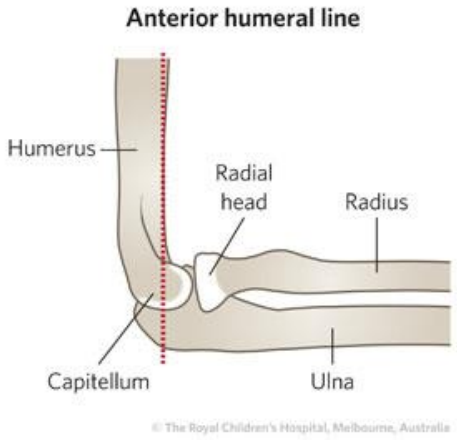

Depending on the location of the proximal aspect of the fracture, patients may exhibit median or radial nerve injuries. Proximal displacement of the fracture fragment may penetrate the brachial artery, as well as damage the median nerve, resulting inability to flex the wrist, or activate flexors of the thumb or digits. Lateral displacement of the fracture fragment may cause radial nerve damage resulting in failure to extend the wrist, supinate, or extend the thumb. Brachial artery injuries may include either disruption of the artery or thrombus. Compartment syndrome will typically present within the first 12-24 hours, and patients should be evaluated for compartment firmness, pain, paleness, pulseless, and cool extremity. Most nerve injuries resolved within 2 to 3 months, after which additional imaging or operative evaluation may be required

Patients with type I fractures may be discharged with a posterior splint and follow-up, patients with type II and type III fractures require orthopedic consultation prior to disposition.

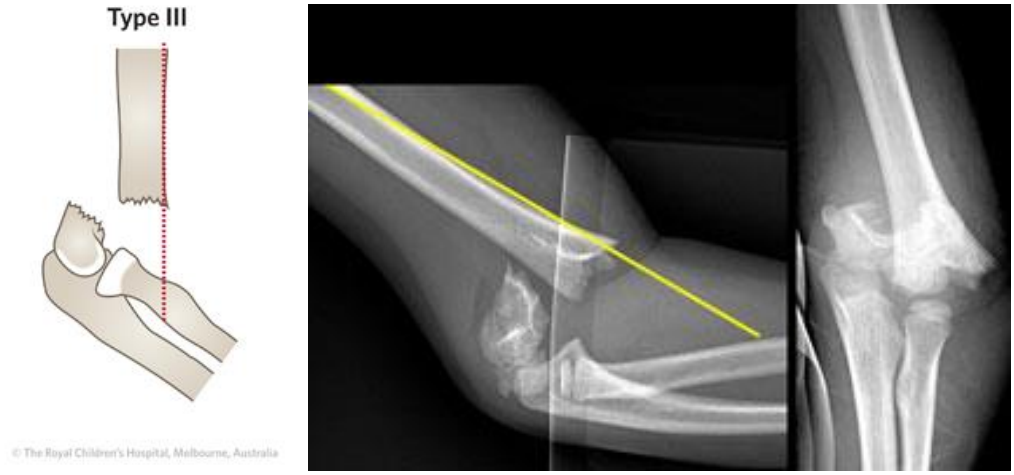

Detection of Arterial Injury in Penetrating Extremity Trauma

Penetrating extremity trauma is frequently encountered in trauma centers, 50% related to handgun injuries. Evaluation for arterial injuries has been debated, with differing sets of practice guidelines, with variable definitions of “hard and soft signs” however most guidelines recommend immediate exploration an operating room for hard signs of vascular injury[1]. Patients who present with an equivocal examination or soft signs of injury, warrant further evaluation with ankle-brachial indexes or arterial imaging. Previous systematic reviews have identified the physical examination and ankle-brachial index as index testing, and if normal may identify patients who do not require CT angiography. Normal physical examination with normal ABI, had a posttest probability of arterial injury of 0%. Positive ankle-

brachial indices had a posttest probability of 9% for arterial injury, while positive ultrasonography had a posttest probability of 89%, with a negative Doppler ultrasound having a 5% posttest probability of arterial injury[1].

Current recommendations are to obtain and ankle-brachial index, and if abnormal obtain further imaging. The utilization of point-of-care ultrasound is not currently part of guidelines, and is operator dependent, with no prospective studies identifying ultrasound as high enough sensitivity to identify arterial injuries. While a positive ultrasound may obviate CTA, negative ultrasound cannot independently exclude arterial injury, and may have a false negative rate of significance[1].

Table 1
Definition of Hard and Soft Signs by EAST and WTA Guidelines

Guideline	Hard Sign	Soft Sign
EAST	Expanding hematoma Bruit Thrill Pulse deficit Pulsatile bleeding	History of arterial bleeding Proximity of wound to artery Neurologic deficit Nonexpanding hematoma
WTA	Expanding hematoma Bruit Thrill Pulselessness Pallor Paresthesia Pain Paralysis External bleeding	History of arterial bleeding Proximity of wound to artery Neurologic deficit Small, nonpulsatile hematoma

EAST = Eastern Association for the Surgery of Trauma; WTA = Western Trauma Association.

Utilization of Doppler and color Doppler in evaluation of vascular injuries

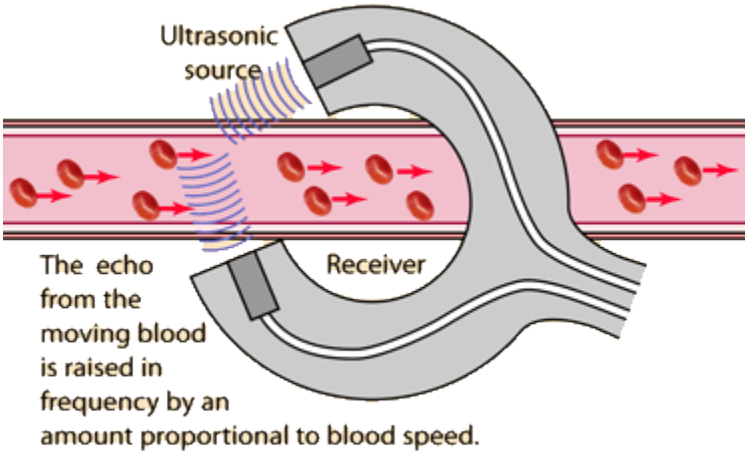

Doppler ultrasound is a noninvasive test which detects the flow of blood by utilizing high-frequency sound waves. Detecting the pulse with a fingertip is qualitative and cannot provide any information on the flow within the vessel. Unlike the identification of a pulse on physical exam, Doppler ultrasound detects actual movement of blood. Abnormal Doppler ultrasounds may detect decreased flow due to surrounding forces being pressed on the arterial wall, or intrinsic abnormalities such as vascular disruption or tears.

2

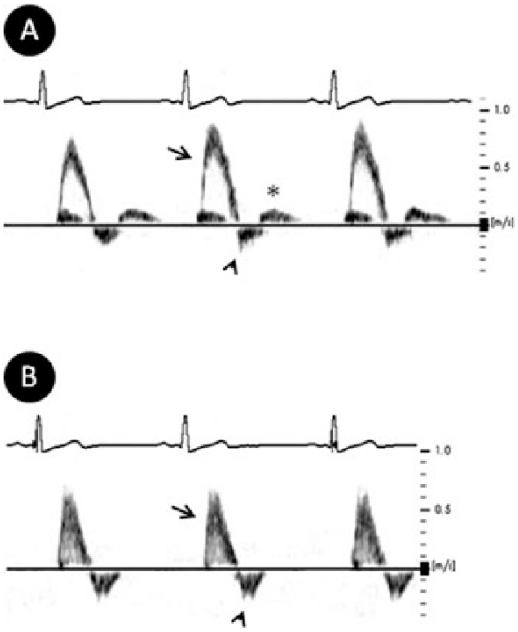

A normal individual will exhibit a tri-phasic Doppler waveform, related to the forward systolic flow, flow reversal, and secondary forward component[3]. Patients with vascular injury will exhibit a biphasic or monophasic waveform, however literature shows that even medical sonographers misidentify approximate 30% of abnormal waveforms[3]. Waveform characterization is subjective and dependent on the experience of the interpreter[3]. Despite differences in identification of waveforms, duplex ultrasound still remains the preferred method for initial evaluation for arterial injuries, with the sensitivity of 95 to 97%[4].

Color Doppler ultrasound involves the utilization of B-mode and Doppler ultrasound together. B-mode ultrasound provides a two-dimensional image through the plane of the body and is frequently used in point-of-care ultrasound and vascular access. In conjunction with B-mode, the application of Doppler ultrasound allows for visual evaluation of flow, including direction. This is frequently applied in the evaluation of intra-abdominal organs, such as ovarian torsion, renal blood flow, and other diagnostics. Currently there are few studies

regarding the use of focused Doppler ultrasound to detect vascular injuries in penetrating extremity trauma. Recent literature has utilized point-of-care ultrasound to evaluate lower extremity missile injuries, however has identified limitations including misidentification of chronic versus acute injuries, misinterpretation of results, and failure to detect proximal injuries without an abnormal distal pattern[4]. In injuries without distal extension such as profunda femoris artery injury, or injuries without hematomas compressing distal flow, a false negative ultrasound would be obtained. Because of the lack of supportive literature, as well as the potential for missed injuries, point-of-care ultrasound is not currently recommended for rapid evaluation of penetrating extremity trauma, and if utilized should be followed by more substantial imaging.

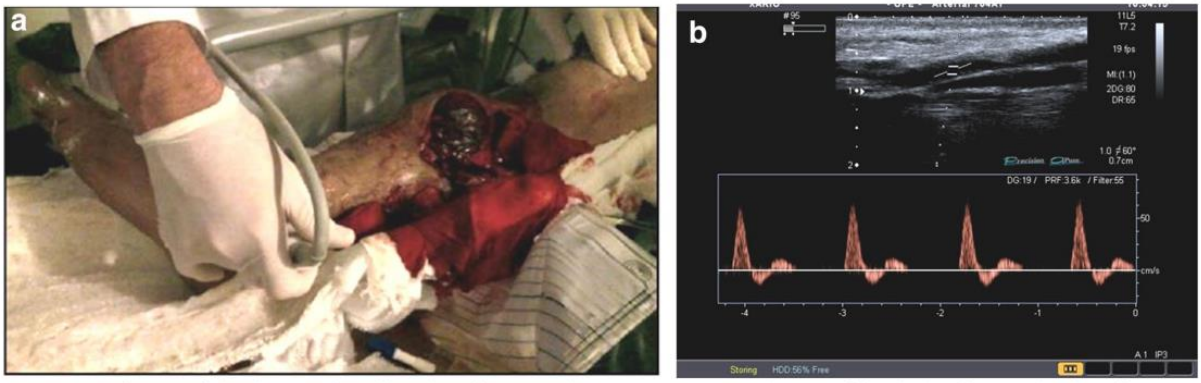

Fig. 19 Open fracture of the tibia. **a** Displaced long bone fracture with segment exposure. Exploration of distal pulses. **b** Normal triphasic flow

5

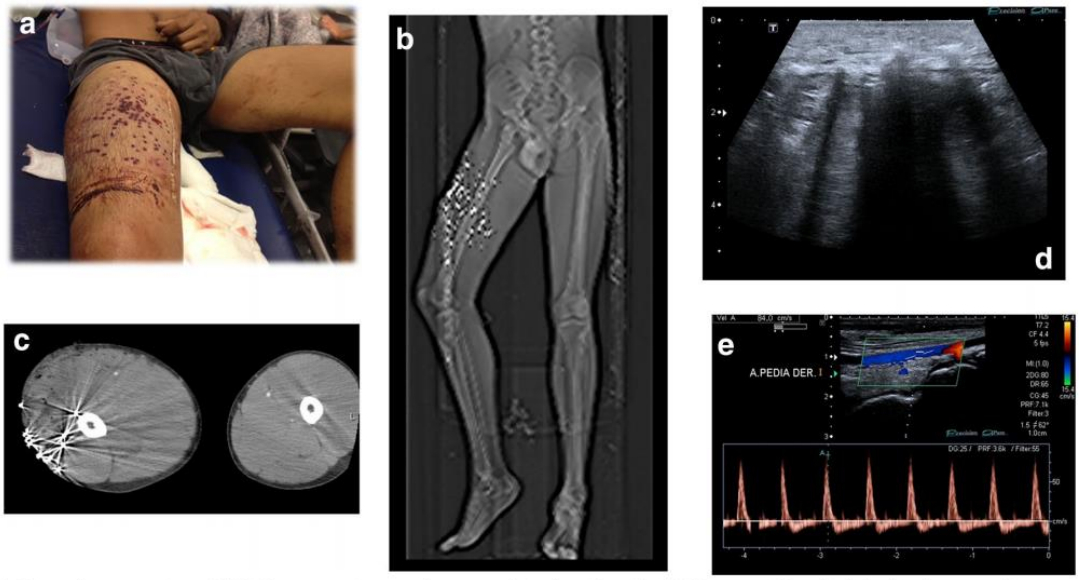

Fig. 20 External compression. **a** Multiple penetrating gun shot wounds in the right tight. **b** CT scan. **c** CT multiple bullets. Increase diameter of the right tight. **d** Ultrasound showed the metallic foreign bodies with acoustic shadow and edema of the soft tissues. **e** Color Doppler showed no vascular lesion in the right tight Pulse wave Doppler showed lost of the triphasic normal flow in distal arteries caused by external compression of the arteries cause by edema and tumefaction

1. deSouza IS, Benabbas R, McKee S, et al. Accuracy of Physical Examination, Ankle-Brachial Index, and Ultrasonography in the Diagnosis of Arterial Injury in Patients With Penetrating Extremity Trauma: A Systematic Review and Meta-analysis. *Acad Emerg Med.* 2017;24(8):994-1017.
2. Fadel BM, Bakarman H, Al-Admawi M, Bech-Hanssen O, Di Salvo G. Pulse-wave Doppler interrogation of the abdominal aorta: a window to the left heart and vasculature. *Echocardiography.* 2014;31(4):543-547.
3. Scissons R. Characterizing Triphasic, Biphasic, and Monophasic Doppler Waveforms. *Journal of Diagnostic Medical Sonography.* 2008;24(5):269-276.
4. Montorfano MA, Montorfano LM, Perez Quirante F, Rodriguez F, Vera L, Neri L. The FAST D protocol: a simple method to rule out traumatic vascular injuries of the lower extremities. *Crit Ultrasound J.* 2017;9(1):8.
5. Montorfano MA, Pla F, Vera L, Cardillo O, Nigra SG, Montorfano LM. Point-of-care ultrasound and Doppler ultrasound evaluation of vascular injuries in penetrating and blunt trauma. *Crit Ultrasound J.* 2017;9(1):5.